

Occupational Pulmonary Aluminosis: A Case Report

Petra SMOLKOVÁ^{1*}, Marie NAKLÁDALOVÁ¹, Tomáš TICHÝ²,
Marie HAMPALOVÁ³ and Vítězslav KOLEK⁴

¹Department of Occupational Medicine, Faculty of Medicine and Dentistry, Palacký University Olomouc, Czech Republic

²Department of Clinical and Molecular Pathology, Faculty of Medicine and Dentistry, Palacký University Olomouc, Czech Republic

³Regional Public Health Authority of the Zlín Region, Czech Republic

⁴Department of Respiratory Medicine, Faculty of Medicine and Dentistry, Palacký University Olomouc, Czech Republic

Received September 10, 2012 and accepted December 17, 2013

Published online in J-STAGE January 15, 2014

Abstract: The authors present a case of occupational lung damage from exposure to dust containing aluminium. The first detected objective pathological finding was that of dispersed micronodules in the lungs seen in a chest radiograph. The final diagnosis of pulmonary aluminosis was established after three years of gradual exclusion of other interstitial lung diseases. The diagnosis was supported by the occupational history confirmed by hygiene assessment of the patient's workplace and especially by histological examination with elemental analysis of the lung tissue. The possibility of development of this rare condition should not be underestimated in workers at high-risk jobs.

Key words: Pulmonary aluminosis, Aluminium, Aluminium compounds, Fibrosis, Pneumoconiosis, Occupational exposure

Introduction

The term “aluminium lung” was first used by Goralowski in the 1940s¹. In the current literature, there are no arguments about the existence of lung damage from inhalation exposure to dust containing aluminium particles or compounds, the so-called aluminosis. Pulmonary aluminosis is defined as pneumoconiosis caused by the presence of dust containing aluminium in the lung tissue². The condition is clinically significant in that it may result in pulmonary fibrosis. There were reports of cases of death

even after few years from the onset of symptoms, e.g. after 3 or 5 yr^{3, 4}.

Radiographic findings may vary considerably, showing nodular or slightly irregular opacities that may merge into more prominent formations, most frequently in the upper lung fields^{6, 7, 10, 11}). Some authors also reported their distribution in the lower lung fields^{10, 11}) or, less frequently, a diffuse micronodular pattern^{4, 12}), as seen in our patient. Possible mediastinal enlargement was also mentioned by some authors¹³). In advanced stages, severe pulmonary fibrosis with honeycombing was described^{5, 7, 12, 14}).

As in other pneumoconioses, there is no effective targeted therapy for aluminosis.

*To whom correspondence should be addressed.

E-mail: smolkova.p@gmail.com

©2014 National Institute of Occupational Safety and Health

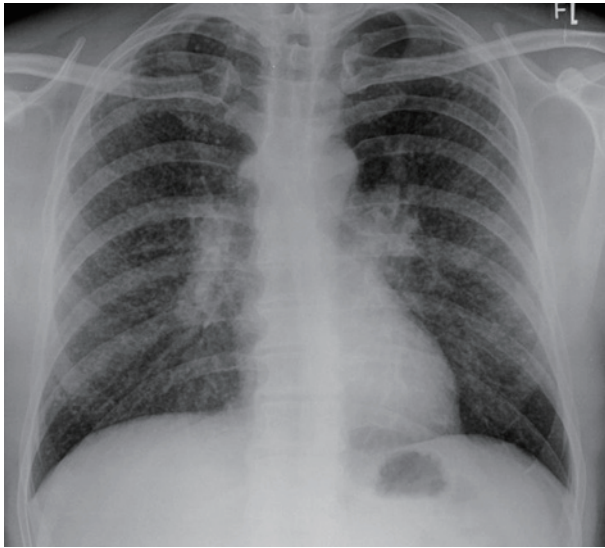


Fig. 1. Patient's plain chest radiograph with numerous dispersed micronodules and bilateral hilar enlargement.

Case Report

The patient was a 39-yr-old male non-smoker. His personal and family history was unremarkable, the only exception being pulmonary sarcoidosis of his cousin.

The first symptoms of the disease were noticed in September 2006 and included severe exertional dyspnoea with non-productive cough. The patient was afebrile, with a BMI of 26.64. Otherwise, physical examination including lung auscultation showed no abnormalities. At that time, a plain chest radiograph revealed numerous dispersed micronodules with bilateral hilar enlargement (Fig. 1). Gallium scintigraphy showed bilateral hilar lymph node enlargement and diffuse uptake of the radiopharmaceutical in both lungs. An HRCT scan of the lungs showed diffuse small foci and enlarged intrathoracic lymph nodes. Bronchoalveolar lavage repeatedly showed no signs of lymphocytic alveolitis considered in differential diagnosis. Spirometry results including diffusing capacity were normal. As a part of the differential diagnosis of dyspnoea with non-productive cough, video-assisted thoracoscopic surgery (VATS) was performed and lung biopsy specimens were obtained in October 2006. The surgically excised material was fixed in 10% formalin and embedded in paraffin. Histological sections of 3–4 μm were stained with haematoxylin and eosin using the PAS (Periodic Acid Schiff) method, as described by Van Gieson, Gomori and Perl. Immunohistochemistry tests were performed using a two-step indirect method with antibodies against S-100

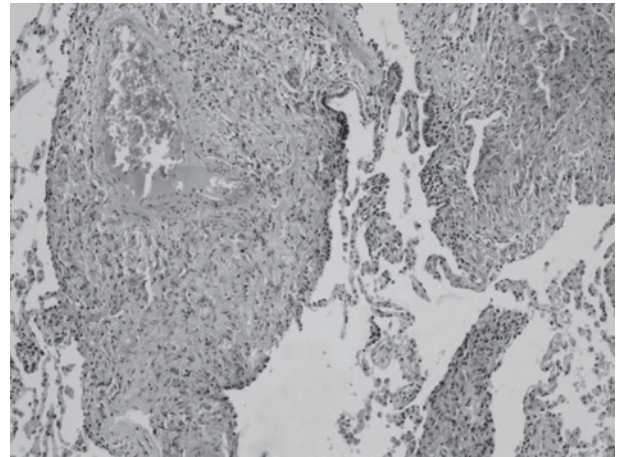


Fig. 2. Perivascular and peribronchial histiocytic and non-granulomatous infiltrates in collapsed lung tissue in a more detail (haematoxylin and eosin stain, 200 \times magnification).

protein, CD68 and CD1a. Histologically, an exudative and proliferative process was described in the lung tissue, with nodular histiocytic infiltrates. The final diagnosis made at a local respiratory clinic was stage II to III sarcoidosis. Systemic corticosteroids were administered for 10 months, until August 2007, but with no therapeutic effect.

Therefore, the histological preparation from the original VATS biopsy was reassessed in November 2007 at the university hospital. The lung infiltrates were histiocytic and non-granulomatous, different from well formed granulomas in sarcoidosis. No microcrystalline particles were found and immunohistochemistry (CD68 positive, S-100 protein and CD1a negative) was not consistent with Langerhans cell histiocytosis. The interstitial fibrosis was mild (Fig. 2). Without detailed knowledge of occupational history, the histopathologist established the diagnosis of non-Langerhans cell histiocytosis suggestive of Erdheim-Chester disease.

Corticoid therapy was reintroduced, this time together with cyclophosphamide. Although Erdheim-Chester disease is a condition characterized by both skeletal and extraskelatal lesions, no typical skeletal changes were seen in a December 2007 PET/CT scan. Bone lesions were not even confirmed by three-phase bone scintigraphy a month later. Both PET/CT and HRCT scans were only suggestive of multiple diffuse micronodules in the lungs.

After another year of the above therapy, the patient's clinical condition remained unchanged, with persisting exertional dyspnoea and non-productive cough. Small disseminated lesions seen on a chest radiograph were unchanged, both pulmonary mechanics and diffusing capac-

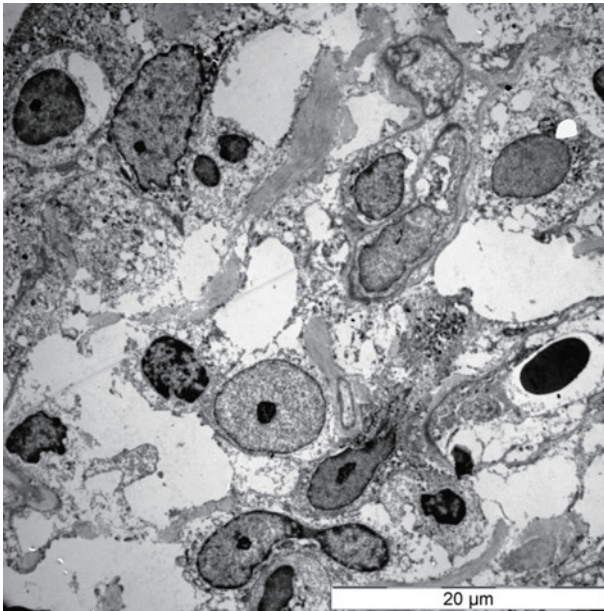


Fig. 3. Electron microscope image of histiocytes with nuclei and ample, in part vacuolated cytoplasm with depositions of electron-dense granular material. Microcrystalline particles were not found. Fibrotic areas are also apparent.

ity were normal. No significant abnormalities were found by biochemistry, immunology and haematology tests. Given the poor response to therapy and regarding the fact that Erdheim-Chester disease was not clinically confirmed, the histological sample was assessed for the third time in January 2009, using an electron microscope. The material for electron microscopy was fixed with glutaraldehyde and osmium tetroxide and embedded in Epon. Ultra-thin slices were stained with lead citrate and uranyl acetate. Elemental analysis of the sample was performed with the EDAX system for X-ray structural analysis. It revealed in particular the presence of aluminium (later also iron pigments and their silicon compounds including elements from the above fixing agents).

The basic histiocytic morphology of the lung involvement and results of elemental analysis corresponded with those in pneumoconiosis (Fig. 3).

Subsequently, therapy with corticoids and cyclophosphamide was discontinued in April 2009. A more detailed occupational history was taken which revealed that the patient had approximately 10-yr occupational exposure to aluminium-containing dust. In his last job between 2000 and 2006, he worked as an aviation mechanic, grinding and polishing aluminium sheets.

After the diagnosis of aluminosis was suspected, in order to classify the condition as an occupational disease,

occupational exposure had to be objectively verified at the patient's workplace by industrial hygiene specialists.

But there were several factors which made this hygienic assessment more difficult: the patient's employer did not measure relevant risk factors associated with performing the job of an aviation mechanic. Then the factory changed the owner and at the time when hygienic assessment was performed, working conditions and technologies were different as well. Because of that the exact measurement of the airborne concentrations of aluminium at the workplace could not be accomplished. However, working conditions and time proportion of particular working operations were specified on the basis of the information obtained from patient's former factory supervisors and material specifications of the used aluminium sheets.

It was found that in his late job of an aviation mechanic, the patient was exposed to fine aluminium dust. This was the most significant and massive exposure which resulted mainly from machine grinding of aluminium materials (sheets containing as much as 92% of aluminium) and their polishing with a hand-held drill and angle grinder. These activities accounted for approximately 25% of his working time. An extremely dusty seasonal work was the so-called airplane refurbishment, with sheet grinding including removal of anodic films accounting for up to 80% of the working time.

The hygienic conditions at the workplace were generally unsatisfactory. The place was only naturally ventilated through windows and gates, with dust constantly raised. Personal protective equipment was inadequate as simple cloth dust masks could not sufficiently protect from exposure to fine aluminium dust.

Thus, according to the industrial hygiene specialists' statement, conditions in the patient's workplace met the criteria for the development of an occupational disease.

Later, approximately 5 yr after the exposure was discontinued, increased aluminium concentration in the patient's serum was also confirmed, reaching 656 nmol/l (reference range, 100–400 nmol/l).

Gradual exclusion of previous suspected diagnoses (sarcoidosis, Erdheim-Chester disease), a lack of response to therapy, the patient's occupational history and especially the histological electron microscopy finding, together with increased serum aluminium level led to the establishment of a diagnosis of pulmonary aluminosis. In 2011, the diagnosis was recognized and the patient was compensated for an occupational disease.

Discussion

The presented case documents differential diagnostic assessment of exertional dyspnoea and non-productive cough with radiographically detected multiple dispersed micronodules in the lungs. Apart from histological diagnosis using electron microscopy with elemental analysis of tissue, the key role was played by a detailed occupational history objectively verified by hygiene assessment and confirmation of occupational exposure to significant amounts of fine aluminium dust.

As early as in 1936, the effect of aluminium-containing dust inhalation on human health was studied in Great Britain. At that time, however, the relationship between aluminium-containing dust inhalation and pulmonary fibrosis was not found¹⁵. The first cases of lung damage from exposure during aluminium processing were reported in the 1930s in Germany. In 1934, Baader reported the first case ever of pulmonary fibrosis associated with the above exposure, as mentioned in a 1938 study by Doese¹⁶. Then, in the 1940s, damage to the lungs from aluminium-containing dust inhalation was extensively studied by Goralewski². In 1960, Koelsch reported that between 1943 and 1960, twenty-seven cases of pulmonary aluminosis were recognized and compensated in Germany^{14, 18}.

Moreover, in the 1940s, thirty-five cases of pulmonary fibrosis were reported among 344 Canadian aluminium potroom workers with exposure in the manufacture of alumina abrasive. Of those, ten died due to respiratory failure⁴.

Traditionally, the highest risk with respect to potential lung damage is associated with processes in bauxite smelting, the use of fine aluminium powder in the manufacture of explosives, and aluminium welding⁸. Some studies reported occasional cases of aluminosis from grinding and polishing of aluminium materials, similar to the presented case^{5, 8, 9}.

In 1986, De Vuyst and colleagues published a case of a metal polisher doing his job for 24 yr, using abrasives to polish aluminium materials mainly in the second half of his exposure and developing a severe form of interstitial lung fibrosis with honeycombing and emphysema⁸. Necropsy findings revealed a diffuse interstitial fibrosis with increased collagen and moderate infiltration with mononuclear cells. Electron microscopy revealed alveolar and septal macrophages exhibiting phagolysosomes with electron-dense content. Elemental analysis of BAL, lung tissue and lymph node tissue samples confirmed aluminium as the most abundant mineral⁸, similarly to our case.

More recently, Kraus *et al.* in their 2006 article reported lung changes in workers in two German plants producing aluminium powder who had been exposed to a mixture of aluminium particles and various lubricants. The changes were detected by HRCT in 15 out of 62 workers, including 2 polishers⁹.

As summarized by Krewski *et al.* histological findings in aluminosis are most typical for the presence of pulmonary fibrosis of various extent and in many cases confirmed presence of particles containing aluminium⁵. Both of these were confirmed in our case. But sporadic findings such as extensive interstitial granulomas were described as well¹².

There have been extensive discussions in the literature regarding the pathophysiological basis of aluminosis and many authors asked what is behind the ability of aluminium to cause lung tissue fibrosis. A range of potential influencing pathophysiological and environmental factors were studied: existence of fibrous particles of alpha aluminium oxide⁴, the role of aluminium oxides and their low temperature transitional forms (such as gamma aluminium oxide)^{4, 10} or the impact of processing aluminium powder, namely the role of additives and lubricants¹⁷. Other authors suppose that an important and dangerous role is played by inhalation of fine dust with respirable aluminium particles sized 0.5–5 μm ⁷. Some of these hypotheses were not supported, several authors concluded that the previous suggestions relating aluminium-induced fibrosis to the presence of gamma aluminium oxide had not been correct^{4, 11}.

However, the pathophysiology of pulmonary aluminosis has not been fully explained as yet.

Conclusion

Although pulmonary aluminosis is a very rare disease, it still occurs. Since the industrial importance and use of aluminium continue to rise, lung damage from exposure to aluminium should not be overlooked, from the perspective of both possible diagnostic considerations and prevention. It is therefore desirable to monitor and minimize exposure to respirable aluminium particles and to try to detect early stages of the disease as well.

Acknowledgement

This research was supported by the Czech Ministry of Health, grant no. NT11117.

References

- 1) Goralewski G (1948) The aluminium lung: a new industrial disease. (Abstract of Goralewski, 1947). *Br J Ind Med* **6**, 53–4.
- 2) Dorland WA (2009) *Dorland's pocket medical dictionary*, 28th Ed., 31, Elsevier Saunders, Philadelphia.
- 3) Ueda M, Mizoi Y, Maki Z, Maeda R, Takada R (1958) A case of aluminum dust lung: a necropsy report. *Kobe J Med Sci* **4**, 91–9.
- 4) Gilks B, Churg A (1987) Aluminum-induced pulmonary fibrosis: do fibers play a role? *Am Rev Respir Dis* **136**, 176–9.
- 5) Krewski D, Yokel RA, Nieboer E, Borchelt D, Cohen J, Harry J, Kacew S, Lindsay J, Mahfouz AM, Rondeau V (2007) Human health risk assessment for aluminium, aluminium oxide, and aluminium hydroxide. *J Toxicol Environ Health B Crit Rev* **10** Suppl 1, 1–269.
- 6) Parkers WR (1994) *Occupational lung disorders*, 3rd Ed., 594–97, Butterworth-Heinemann Ltd, Oxford.
- 7) Guidotti TL (1975) Pulmonary aluminosis —a review. *Toxicol Pathol* **3**, 16–8.
- 8) De Vuyst P, Dumortier P, Rickaert F, Van de Weyer R, Lenclud C, Yernault JC (1986) Occupational lung fibrosis in an aluminium polisher. *Eur J Respir Dis* **68**, 131–40.
- 9) Kraus T, Schaller KH, Angerer J, Hilgers RD, Letzel S (2006) Aluminosis—detection of an almost forgotten disease with HRCT. *J Occup Med Toxicol* **1**, 4.
- 10) Townsend MC, Sussman NB, Enterline PE, Morgan WKC, Belk HD, Dinman BD (1988) Radiographic abnormalities in relation to total dust exposure at a bauxite refinery and alumina-based chemical products plant. *Am Rev Respir Dis* **138**, 90–5.
- 11) Jederlinic PJ, Abraham JL, Churg A, Himmelstein JS, Epler GR, Gaensler EA (1990) Pulmonary fibrosis in aluminum oxide workers. Investigation of nine workers, with pathologic examination and microanalysis in three of them. *Am Rev Respir Dis* **142**, 1179–84.
- 12) Chen WJ, Monnat RJ Jr, Chen M, Mottet NK (1978) Aluminum induced pulmonary granulomatosis. *Hum Pathol* **9**, 705–11.
- 13) Ansell G (1998) *Imaging drug reactions and toxic hazards*, 3rd Ed., 9, Hodder Arnold, London.
- 14) Mitchell J, Manning GB, Molyneux M, Lane RE (1961) Pulmonary fibrosis in workers exposed to finely powdered aluminium. *Br J Ind Med* **18**, 10–23.
- 15) Hunter D, Milton R, Perry KMA, Thompson DR (1944) Effect of aluminium and alumina on the lung in grinders of duralumin aeroplane propellers. *Br J Ind Med* **1**, 159–64.
- 16) Doese M (1938) Industrial medicine studies on injury to health caused by aluminium, in particular lung disease from aluminium dust. *Arch Gewerbepathol* **8**, 501–31.
- 17) Dinman BD (1987) Aluminum in the lung: the pyropowder conundrum. *J Occup Med* **29**, 869–76.
- 18) Koelsch F (1942) Pulmonary disease caused by aluminum dust. *Beitr Klin Tuberk* **97**, 688–93. 1960 – Private communication, cited by Mitchell et al.